

Predictive Lymphatic Mapping

A Method for Mapping Lymphatic Channels in Patients With Advanced Unilateral Lymphedema Using Indocyanine Green Lymphography

Makoto Mihara, MD,* Yukio Seki, MD,* Hisako Hara, MD,* Takuya Iida, MD,* Aiko Oka, MD,* Kazuki Kikuchi, MD,* Mitsunaga Narushima, MD,* Makiko Haragi, MFA,* Dominic Furniss, MD,† Lawrence Hin-Lun, MD,‡ Kito Mitsui, MD,§ Noriyuki Murai, MD,§ and Isao Koshima, MD*

Abstract: In severe lymphedema, indocyanine green lymphography cannot be used to map lymphatic channels before lymphaticovenular anastomosis (LVA) because linear lymphatics cannot be detected in a severely affected leg. Here, we describe a new method, which we refer to as predictive lymphatic mapping, to predict the location of lymphatics for anastomosis in unilateral lymphedema, thereby improving surgical accuracy and efficiency. The approach consists of marking anatomical landmarks and joining selected landmarks with fixed lines. The distance from these fixed lines to lymphatic channels mapped by indocyanine green lymphography in the unaffected leg is then measured, scaled up based on the difference in circumference between the legs, and transposed to the affected leg. To date, we have used this method in 5 cases of unilateral or asymmetric lymphedema of the lower extremities. In no cases have we failed to find a lymphatic channel suitable for LVA within a 2-cm incision. These results suggest that predictive lymphatic mapping is a useful additional tool for surgeons performing LVA under local anesthesia, which will help to improve the accuracy of incisions and the efficiency of surgery.

Key Words: lymphaticovenular anastomosis, lymphedema, preoperative mapping, LVA, ICG lymphography, lymphoscintigraphy, lymphatic mapping, collecting lymphatic vessel

(*Ann Plast Surg* 2013;00: 00–00)

Lymphaticovenular anastomosis (LVA) is an excellent treatment option for lymphedema of the lower extremities, based on its efficacy and low morbidity.^{1–5} Lymphaticovenular anastomosis can be performed under local anesthesia, which eliminates the risks of general anesthesia and allows the procedure to be undertaken in patients with significant medical comorbidities.⁶ To undertake LVA under local anesthesia, the surgeon must determine the anatomical location of the lymphatic channels underneath the skin. This allows short incisions, commonly under 2 cm in length, to give access to both the lymphatic channel and a subdermal venule for LVA, and this procedure is

generally well tolerated. However, it is sometimes very difficult to detect lymphatic vessels that are suitable for anastomosis especially in severe lymphedema cases, and surgeons are forced to close the incision without any anastomosis if suitable lymphatics are not found.

Indocyanine green (ICG) lymphography is a useful and minimally invasive imaging modality^{7,8} that allows staging of lymphedema.⁹ Indocyanine green lymphography can also be used for preoperative determination of the location of functioning subcutaneous lymphatic channels, which appear as a linear pattern, and subsequent planning of an effective, short incision for LVA.¹⁰ However, in advanced stages of lymphedema (leg dermal backflow stages III–V), linear patterns on ICG lymphography are not seen above the ankle, making selection of the incision site more difficult. This can lead to longer incisions, a longer operating time, and even the inability to find a lymphatic channel within a particular incision.

Many patients with lymphedema are affected unilaterally or mildly affected in one leg compared with the other. This is also reflected in ICG lymphography findings. For clarity, we will refer to the lesser affected leg as “unaffected” throughout the rest of this report. Based on our experience that lymphatic channels are distributed symmetrically within the lower leg, we developed a system of predictive lymphatic mapping. This approach uses the relationship between fixed points and lymphatic channels on the unaffected leg detected with ICG lymphography to predict the position of lymphatic channels in the affected leg, taking into account the difference in size between the 2 limbs. To increase the efficiency of surgery, we also used AccuVein (Accuvein Inc, NY), which visualizes veins through the skin.^{11,12} Here, we describe predictive lymphatic mapping in detail and present our initial clinical experience with the technique.

METHODS

Subjects

Preoperative lymphatic mapping and LVA were performed in 5 patients (5 legs) with unilateral leg lymphedema between November 2011 and January 2012 (Table 1). All patients were female and were 32 to 72 years old (mean, 53.8 years old). All the patients had received conservative treatment (elastic stockings and lymph drainage), but this treatment was ineffective or the condition had aggravated. The lymphedema stage was diagnosed by inspection and palpation following the classification established by the International Society of Lymphology for disease staging. Lymphedema was stage IIa in 3 patients and stage IIb in 2 patients. The study was approved by our institutional review board, and informed consent was obtained from all patients.

Evaluation

Changes in the circumferences of the bilateral lower limbs after surgery and hardness of the affected limb were measured as objective items. The circumference was measured after LVA at the hip and at 4 leg sites: the center of the thigh, 5 cm above and below the

Received March 22, 2012, and accepted for publication, after revision, July 16, 2012.

From the *Department of Plastic and Reconstructive Surgery, The University of Tokyo, Tokyo, Japan; †Department of Plastic and Reconstructive Surgery, Oxford University Hospitals, West Wing, John Radcliffe Hospital, Oxford, United Kingdom; ‡Division of Plastic and Reconstructive Surgery, Department of Surgery, Queen Mary Hospital, Hong Kong; and §Department of Vascular Surgery, Saiseikai Kawaguchi Hospital, Kawaguchi, Saitama, Japan.

Conflicts of interest and sources of funding: The study was supported by the Japanese funding program for next-generation world-leading research (NEXT program; LS039). The study sponsor had no role in the collection of data or writing and submission of the manuscript.

Makoto Mihara, Yukio Seki, and Hisako Hara contributed equally to this work. Reprints: Makoto Mihara, MD, Department of Plastic and Reconstructive Surgery, The University of Tokyo, 7-3-1 Hongo, Bunkyo-ku, Tokyo, 113-8655, Japan. E-mail: mihara@keiseigeka.name.

Copyright © 2013 by Lippincott Williams & Wilkins
ISSN: 0148-7043/13/0000-0000
DOI: 10.1097/SAP.0b013e31826a18b1

TABLE 1. Cases Treated With Preoperative Lymphatic Mapping and LVA

Case	Age, y	Sex	Primary Disease	Lymph Node Dissection	Radiation	Lymphedema Period, mo	Side of Diseased Limb	ISL Staging of Lymphedema
1	64	Female	Cervical cancer	+	+	15	Right	IIb
2	45	Female	Endometrial sarcoma	+		30	Left	IIa
3	56	Female	Cervical cancer	+		69	Left	IIb
4	72	Female	Cervical cancer	+	+	60	Right	IIa
5	32	Female	Cervical cancer	+		7	Left	IIb

ISL, International Society of Lymphology.

knee, and the ankle. The percentage of reduction was calculated as the (postoperative circumference/preoperative circumference) \times 100. Improvements to less than 92%, 92% to 98%, and 98% to 102% were evaluated as excellent, good, and fair (unchanged, based on measurement errors), respectively. Hardness was graded as 2, 1, and 0 for regions that were markedly harder, slightly harder, and of the same hardness, respectively, compared with the healthy side.

Predictive Lymphatic Mapping

Step 1: ICG injection and lymphatic imaging. Indocyanine green lymphography was performed by injecting 0.2 mL of ICG (Diagnogreen 0.25%; Daiichi Pharmaceutical, Tokyo, Japan) subcutaneously into the bilateral lower extremities at the first web space of the foot and the lateral border of the Achilles tendon. This procedure was usually performed on preoperative day 1 but must be performed a minimum of 2 hours before operation. All subsequent steps can be performed on preoperative day 1 or just before the operation in the operating room. A minimum of 2 hours after the injection, imaging was performed using a Photo Dynamic Eye system (Hamamatsu Photonics, Hamamatsu, Japan; Fig. 1A). Linear patterns of lymphatic channels were marked on the skin (Fig. 1B). At the same time, lymphedema of the bilateral lower limbs was staged using ICG lymphography (Fig. 1C).

Step 2: Identification of anatomical landmarks and limb measurement. Five anatomical landmarks were identified and marked bilaterally (Fig. 2A, B): the anterior superior iliac spine, the medial border of the patella, the medial malleolus, the lateral malleolus, and the first web space of the foot. Fixed lines were drawn connecting the first web space with each malleolus, each malleolus with the medial border of the patella, and the medial border of the patella with the anterior superior iliac spine (Fig. 2C, D). The circumferences of both limbs were measured at 7 sites: the groins of the bilateral legs, 20 and 10 cm above the knee, the knee, and 10 cm below the knee, ankle, and dorsum of the foot.

Step 3: Predictive lymphatic mapping. On the unaffected side, measurements were taken between the location of the fixed lines (step 2) and the mapped lymphatic channels at the 7 anatomical locations at which the limb circumference was measured (step 2). These distances were then scaled using the ratio of the circumferences of the affected and unaffected legs (Fig. 3A). The calculated distances were then transposed onto the affected leg, and the predicted anatomical location of the lymphatic channel was marked as a predicted lymphatic point (PLP; Fig. 3B, C). Using this procedure, 7 PLPs were marked and then sequentially connected from the dorsum of the foot to the groin of the leg to give a predicted lymphatic line (PLL; Fig. 4A). After the PLL was established and subcutaneous veins were identified using AccuVein, 2-cm or smaller skin incisions for LVA were planned at sites near to or crossing this line.

RESULTS

We have used predictive lymphatic mapping in 5 cases of unilateral or asymmetric lymphedema of the lower extremities. The

operative characteristics of these cases are given in Table 2. A lymphatic channel suitable for LVA within the 2-cm incision was found in all 5 cases. The number of skin incisions in the affected limb was 3 to 5 (mean, 4), and the number of LVAs applied in the affected limb in each patient was 5 to 9 (mean, 6.6). The operation time was 190 to 292 minutes (mean, 233.8 minutes). Changes in the circumference after surgery were rated as good in 4 cases and fair in 1. The skin tissue hardness improved after surgery in all 5 patients, and there were no postoperative complications. We illustrate the method with a case report for one of these patients.

The patient (case 1) was a 64-year-old Japanese woman who underwent extended hysterectomy with pelvic lymph node dissection and radiation therapy for cervical carcinoma. One month after surgery, she developed progressive lymphedema in the right lower limb. Despite constant and strong compressive therapy with an elastic stocking for 17 months, the lymphedema gradually progressed. On examination, she had right-sided unilateral lymphedema, with increases in the circumferences of the right thigh, right knee, and right calf of 6.5, 4.0, and 1.0 cm, respectively, compared with the left

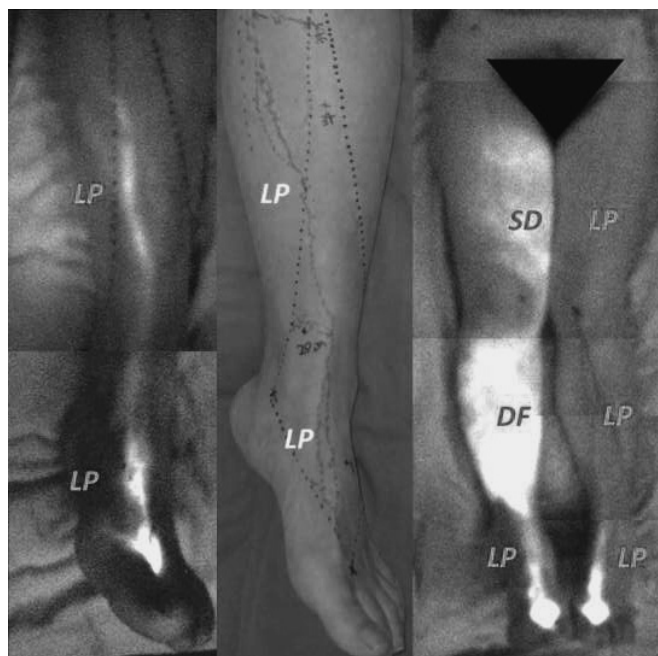


FIGURE 1. Step 1 (case 1). A, Image of normal lymph vessels in the healthy lower limb (LP, linear pattern). B, Skin markings based on ICG lymphography. C, Diagnosis of lymphedema in the bilateral lower limbs using ICG lymphography. Star dust (SD), diffuse (DF), and linear (LP) patterns were noted in the right thigh, right crus, and other regions, respectively.

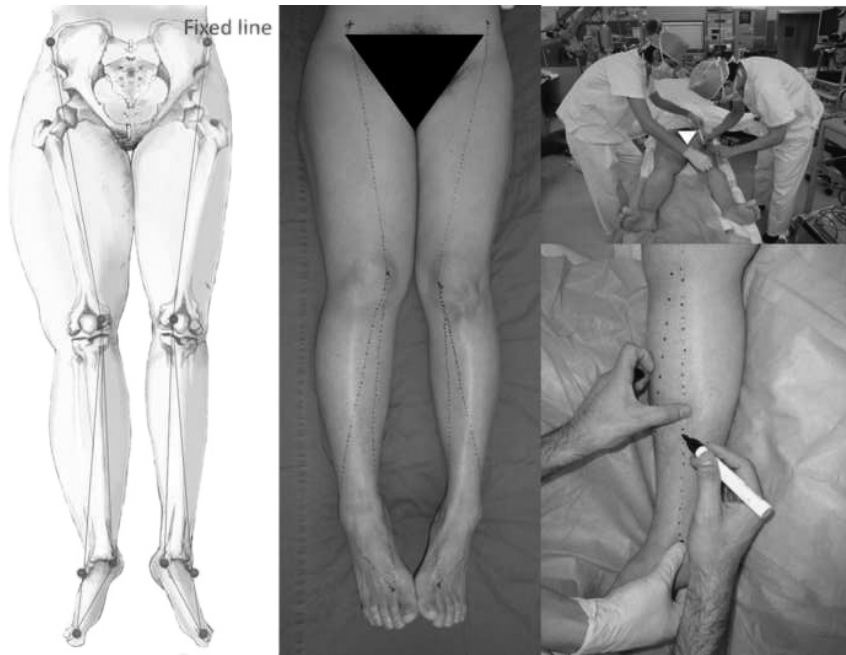


FIGURE 2. Step 2 (case 1). A and B, Anatomical landmarks and preparation of a fixed line. C, Preoperative lymphatic mapping. D, Constructing a fixed line using string.

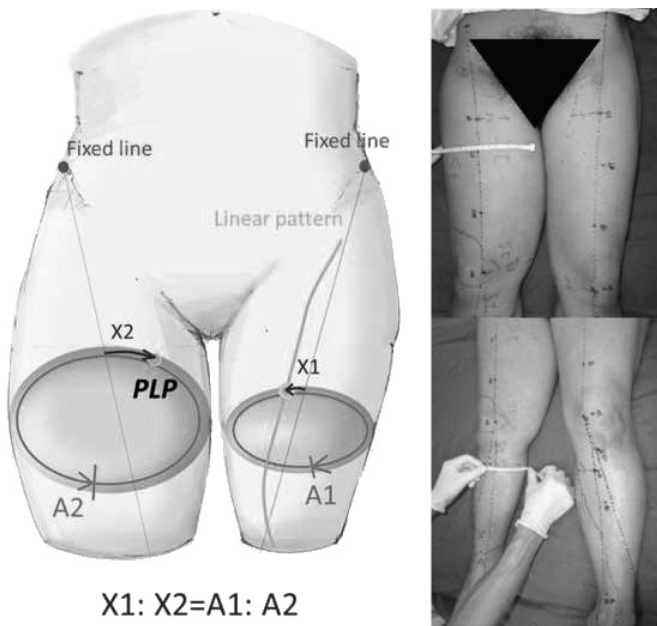


FIGURE 3. Step 3 (case 1). A, Determination of a PLP using the relationship $X1:X2 = A1:A2$, where A1 and A2 are the circumferences of the healthy and affected lower limbs, respectively, X1 is the distance between the fixed line and a normal lymph vessel in the healthy limb, and X2 is the distance between the fixed line and the PLP in the affected limb. B, Marking of a PLP at a site 20 cm above the knee. C, Marking of a PLP at a site 10 cm below the knee.

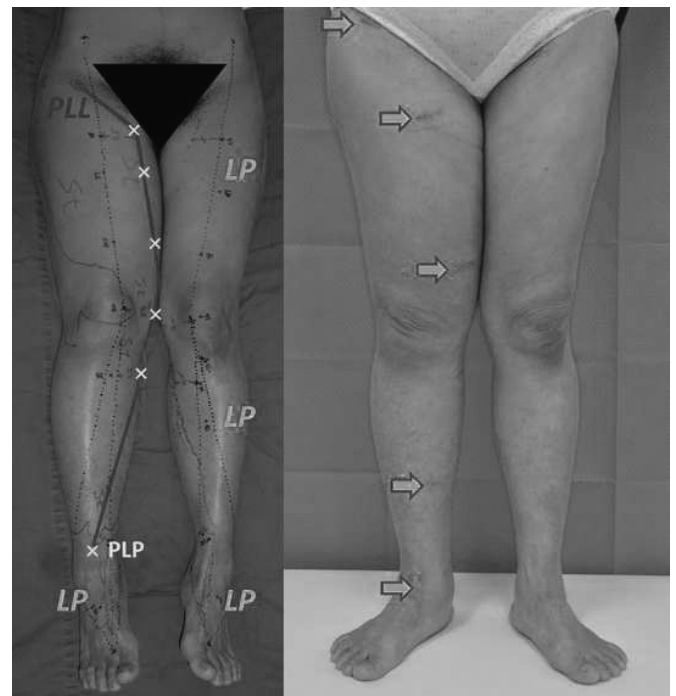


FIGURE 4. A, Step 3 (case 1). A PLL was determined by connecting PLPs in the thigh and crus. LP, linear pattern. B, Case 1 at 1 month after surgery. The circumference of the limb was 95% of the value (100%) before surgery, and the score for skin hardness had improved from 2 to 1. Lymphaticovenular anastomosis was applied at sites indicated with yellow arrows in the affected limb.

TABLE 2. Operative Data for Patients Undergoing LVA

Case	Skin Incisions in Affected Limb	No. LVAs	LVAs/Skin Incisions	Operation Time, min	Circumference Reduction*	Tissue Hardness After LVA†
1	5	9	1.8	237	Good	1
2	3	6	2.0	190	Good	0
3	5	7	1.4	292	Fair	1
4	3	5	1.7	220	Good	1
5	4	6	1.5	230	Good	1

*Change in limb circumference after LVA surgery.

†Tissue hardness before surgery was scored as 2 in each case.

side (Fig. 2B). She opted for LVA surgery to attempt to improve her lymphedema symptoms.

On ICG lymphography, a linear pattern on the right side was seen only on the dorsum of the foot, with a dermal backflow pattern present in the calf, knee, thigh, and hip regions (Fig. 1C). The left limb showed a linear pattern from the dorsum of the foot to the knee and upper thigh. Therefore, we used predictive lymphatic mapping to predict the location of the lymphatic channels in the affected right leg (Fig. 4A). Five incisions were made based on the results of predictive lymphatic mapping, and lymph channels and subcutaneous veins were detected in only a few minutes at all 5 locations. In total, 13 LVAs were completed bilaterally under local anesthesia by 4 surgeons using 4 microscopes, with a total operative time of 3 hours and 57 minutes. Of the 13 anastomoses, 9 were made at the 5 incisions on the right leg that were made based on predictive lymphatic mapping.

Compressive therapy was restarted after surgery. There was rapid improvement of symptoms of lymphedema within a month after surgery (Fig. 4B). The circumference of the lower limb at 1 month after surgery was 95% of that before surgery (100%), and the skin hardness score improved from 2 to 1. At 2 months after surgery, the patient was under course observation, and her symptoms have continued to improve slowly thereafter.

DISCUSSION

This is the first report of a technique to assist in localization of lymphatic channels in limbs with dermal backflow patterns on ICG lymphography. We refer to this technique as predictive lymphatic mapping. Collecting lymph vessels are frequently distributed along the great saphenous vein in the lower limbs. We have previously made incisions along the great saphenous vein, but this method took time to search for lymph vessels, and no lymph vessel appropriate for anastomosis was found in some cases. Using predictive lymphatic mapping, regions in which lymph vessels may be present can be determined, facilitating performance of surgery through small skin incisions. In addition, shortening of the time taken to search for lymph vessels enables application of more LVAs within a specific operation time. These features reduce the invasiveness of the surgery.

We used AccuVein to visualize veins through the skin.^{11,12} Lymphaticovenular anastomosis is applied to veins with a diameter of approximately 0.5 mm, and these veins may be seen through the skin in healthy lower limbs but can barely be seen in limbs with lymphedema. AccuVein is a device that uses infrared and laser technology for noninvasive testing without the use of contrast medium. In LVA, a lymph vessel may be found at a skin incision site, but no vein is found, and this can be the rate-determining step in surgery. Therefore, identification of the position of the cutaneous veins is as useful as identification of lymph vessels.

Imaging modalities used to investigate lymphatic channel function and anatomy include lymphoscintigraphy,^{13,14} magnetic resonance (MR) lymphography,^{15,16} and ICG lymphography.⁷⁻¹⁰ Our

experience has been that the lymphatic channels of a particular patient tend to be symmetrically distributed. In this article, we used this symmetry to describe a system whereby the location of lymphatic channels can be reliably predicted from the position of directly visualized channels in the contralateral unaffected limb. As illustrated by our clinical cases, this predictive lymphatic mapping method facilitates detection of lymph channels intraoperatively for patients with unilateral dermal backflow ICG patterns.

We used ICG lymphography for mapping, but this could also be performed using lymph scintigraphy or MR lymphography. However, we found that ICG lymphography required a shorter time than lymph scintigraphy and also has a higher resolution and does not require radiation exposure. Lymph vessels in the normal lower limbs are imaged as a single thick line on lymph scintigraphy in many cases, but lymph vessels are observed as several lines on ICG lymphography, facilitating accurate mapping of many lymph vessels. The resolution of MR lymphography is higher than that of ICG lymphography, facilitating accurate identification of the positions of lymph vessels on the tomographic image. However, lymph vessels can be localized immediately before surgery or in real time during surgery using ICG lymphography, which enables direct and accurate marking on the skin. In addition, ICG lymphography is applicable in patients with artificial joints and pacemakers.

One limitation of the predictive lymphatic mapping approach is that it is not applicable to patients in whom dermal backflow patterns are present bilaterally to the level of the ankle. Within this limitation, we conclude that this approach is a useful tool for improving the accuracy of incisions in performance of LVA under local anesthesia.

REFERENCES

- O'Brien BM, Sykes P, Threlfall GN, et al. Microlymphaticovenous anastomoses for obstructive lymphedema. *Plast Reconstr Surg.* 1977;60:197-211.
- Campisi C, Davini D, Bellini C, et al. Lymphatic microsurgery for the treatment of lymphedema. *Microsurgery.* 2006;26:65-69.
- Campisi C, Bellini C, Campisi C, et al. Microsurgery for lymphedema: clinical research and long-term results. *Microsurgery.* 2010;30:256-260.
- Narushima M, Mihara M, Yamamoto Y, et al. The intravascular stenting method for treatment of extremity lymphedema with multicongfiguration lymphaticovenous anastomoses. *Plast Reconstr Surg.* 2010;125:935-943.
- Mihara M, Uchida G, Hara H, et al. Lymphaticovenous anastomosis for facial lymphedema after multiple courses of therapy for head-and-neck cancer. *J Plast Reconstr Aesthet Surg.* 2011;64:1221-1225.
- Koshima I, Nanba Y, Tsutsui T, et al. Minimal invasive lymphaticovenular anastomosis under local anesthesia for leg lymphedema: is it effective for stage III and IV? *Ann Plast Surg.* 2004;53:261-266.
- Ogata F, Azuma R, Kikuchi M, et al. Novel lymphography using indocyanine green dye for near-infrared fluorescence labeling. *Ann Plast Surg.* 2007;58:652-655.
- Ogata F, Narushima M, Mihara M, et al. Intraoperative lymphography using indocyanine green dye for near-infrared fluorescence labeling in lymphedema. *Ann Plast Surg.* 2007;59:180-184.
- Yamamoto T, Narushima M, Doi K, et al. Characteristic indocyanine green lymphography findings in lower extremity lymphedema: the generation of a novel lymphedema severity staging system using dermal backflow patterns. *Plast Reconstr Surg.* 2011;127:1979-1986.

10. Yamamoto T, Matsuda N, Doi K, et al. The earliest finding of indocyanine green lymphography in asymptomatic limbs of lower extremity lymphedema patients secondary to cancer treatment: the modified dermal backflow stage and concept of subclinical lymphedema. *Plast Reconstr Surg*. 2011;128:314e–321e.
11. Mihara M, Hara H, Narushima M, et al. Lower limb lymphedema treated with lymphatico-venous anastomosis based on pre- and intraoperative icg lymphography and non-contact vein visualization: A case report. *Microsurgery*. 2012;32:227–230.
12. Mihara M, Hara H, Hayashi Y, et al. Upper-limb lymphedema treated aesthetically with lymphaticovenous anastomosis using indocyanine green lymphography and noncontact vein visualization. *J Reconstr Microsurg*. 2012;28:327–332.
13. Campisi C. Lymphedema: modern diagnostic and therapeutic aspects. *Int Angiol*. 1999;18:14–24.
14. Partsch H. Assessment of abnormal lymph drainage for the diagnosis of lymphedema by isotopic lymphangiography and by indirect lymphography. *Clin Dermatol*. 1995;13:445–450.
15. Lohrmann C, Foeldi E, Bartholoma J-P, et al. Interstitial MR lymphangiography—a diagnostic imaging method for the evaluation of patients with clinically advanced stages of lymphedema. *Acta Tropica*. 2007;104:8–15.
16. Lohrmann C, Foeldi E, Bartholoma J-P, et al. Gadoteridol for MR imaging of lymphatic vessels in lymphoedematous patients: initial experience after intracutaneous injection. *Br J Radiol*. 2007;80:569–573.